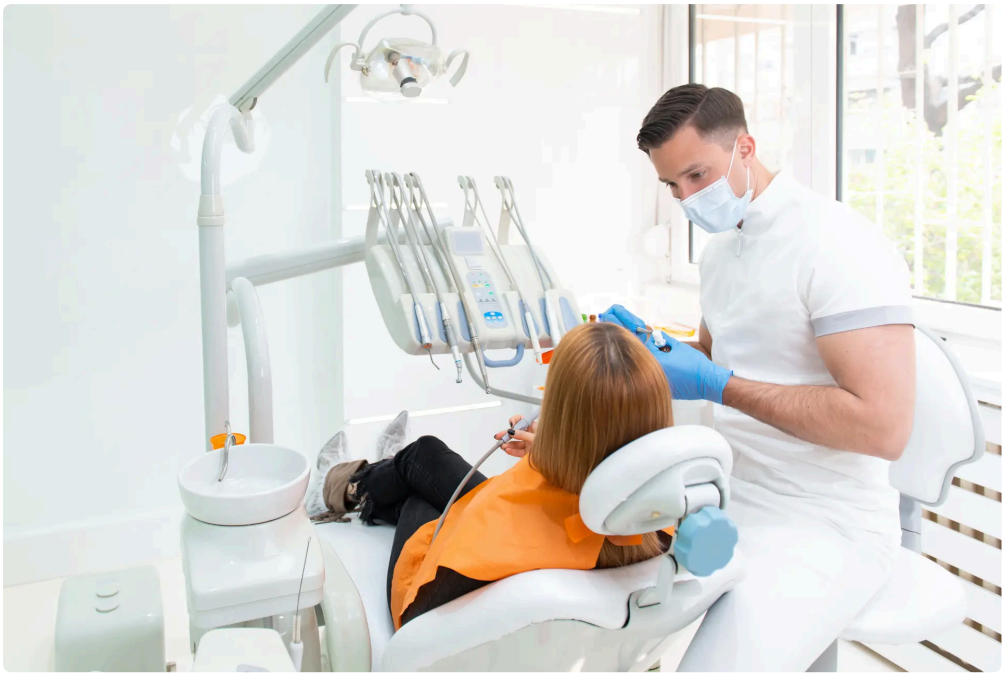

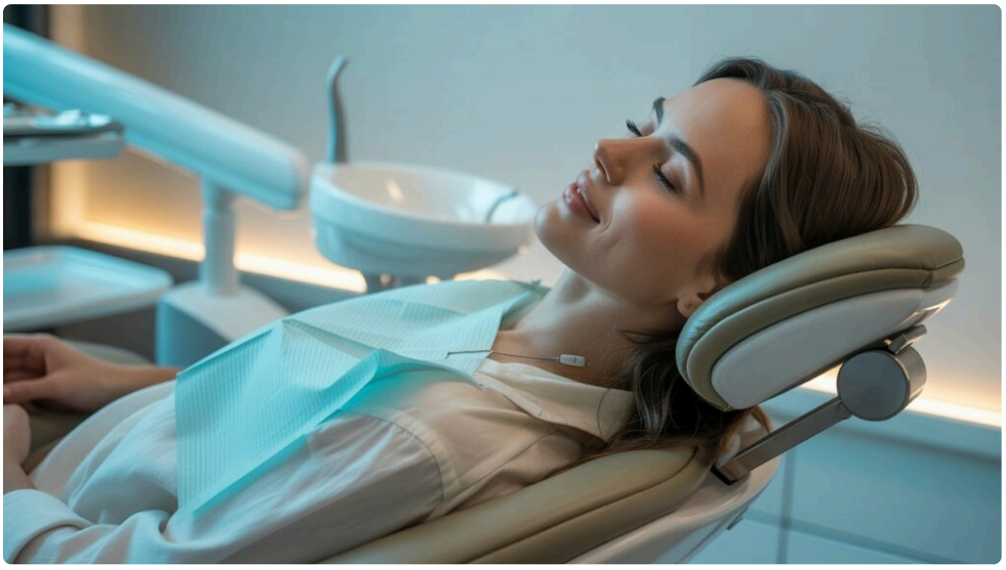

A tooth can fail in an instant. One bite on an olive pit, one elbow during a pickup basketball game, one nighttime grinding episode, and suddenly something feels sharp, loose, or simply wrong. The first question most people ask is practical, not technical: do I need urgent care, or can this wait?

The answer depends less on the appearance of the tooth and more on what else is happening around it. Pain matters. Bleeding matters. Swelling matters. Sensitivity to air or temperature matters. So does whether the damage reaches the nerve, changes your bite, or leaves pieces moving independently. A small chip on the edge of a front tooth can be upsetting but not truly urgent. A crack in a back molar with severe pain when you bite down may not look dramatic at all, yet it can absolutely qualify as a dental emergency.

Dentists see this distinction every day. Some patients walk in holding a large piece of tooth and feel almost no pain. Others arrive with what looks like a tiny fracture line, but the nerve is inflamed and the tooth is screaming. The eye can mislead you. Symptoms, timing, and function tell the real story.

Not every broken tooth is the same problem

People often use the words chipped, cracked, and broken interchangeably, but they describe different injuries, and those differences shape treatment.

A chipped tooth usually means a small fragment has come off, often from the outer enamel. This commonly happens on the edge of a front tooth or the cusp of a molar. If the chip is shallow, there may be no pain at all, just a rough edge that irritates the tongue or lip. In many cases, that can be repaired with smoothing, bonding, or a filling during a prompt but non-emergency visit.

A cracked tooth is more complicated. Cracks can be microscopic or deep, visible or hidden under the surface. Some run through enamel only. Others travel into dentin, the softer layer beneath, where sensitivity tends to begin. A more serious crack can extend toward the pulp, where the tooth’s nerve and blood supply live. That is when pain becomes more likely, especially with biting, release of pressure, cold drinks, or sweet foods.

A broken tooth often means a larger portion has fractured away, sometimes leaving the tooth structurally unstable. Fillings can break off. Old crowns can fail. Decay can hollow a tooth from the inside so that what finally breaks is only the last thin shell. In these cases, the visible event is often the endpoint of a longer process.

Then there is the tooth that is not merely damaged but displaced. If trauma loosens a tooth, pushes it inward, partially out of the socket, or knocks it out entirely, the situation becomes time-sensitive very quickly. That is no longer just a cosmetic issue. It is an urgent injury involving bone, ligament, and long-term tooth survival.

What turns damage into a true dental emergency

The phrase "Dental Emergency" gets used broadly, sometimes too broadly. From a clinical standpoint, urgency is usually tied to one of four concerns: uncontrolled pain, risk of infection, active bleeding, or loss of tooth viability.

If a tooth is chipped but comfortable, stable, and not cutting soft tissue, it may be important without being emergent. If the same tooth exposes the yellow dentin or the pink-red pulp, causes severe temperature sensitivity, or fractures near the gumline, the picture changes. The more deeply the tooth is involved, the less forgiving time tends to be.

Pain is one of the strongest signals. A dull awareness after biting something hard can mean bruising of the ligament or a small crack. Sharp pain on release after chewing is a classic clue that a crack is flexing. Throbbing that wakes you up, lingers for minutes after cold exposure, or radiates into the jaw often points to nerve involvement. Not every painful tooth needs a midnight visit, but severe or escalating pain should not be ignored.

Swelling changes the equation too. Swelling of the gum near the damaged tooth can indicate infection or significant inflammation. Swelling that affects the face, floor of the mouth, or ability to swallow is more serious and can become a medical emergency, not just a dental one.

Bleeding deserves context. A little oozing from the gum after trauma is common. Continuous bleeding, especially from a laceration or from around a loosened tooth, needs timely attention. So does any injury in which the bite suddenly feels off, the tooth moves when touched, or the jaw may have been involved.

A quick rule of thumb that works surprisingly well

If you can answer yes to any of these, treat the situation as urgent and call a dentist right away:

1. The tooth pain is severe, constant, or worsening.
2. The tooth is loose, displaced, or completely knocked out.
3. There is facial swelling, pus, fever, or a bad taste suggesting infection.
4. The break exposes a dark, yellow, or pink inner layer and sensitivity is intense.
5. Bleeding does not stop, or the tooth has left a sharp edge that is injuring your cheek, tongue, or lip.

If none of those apply, the injury may still need care soon, just not emergency care. That distinction matters because early treatment can often save more tooth structure, reduce cost, and prevent a small defect from becoming a root canal or extraction later.

When a chip can wait, and when it should not

Small chips are the most common scenario people underestimate or overestimate, depending on the day. A minor enamel chip without pain often feels like a nuisance more than an emergency, and that is usually accurate. The tooth may simply need polishing or composite bonding. If the piece is from a visible front tooth, aesthetics become part of the urgency from the patient’s point of view, even if the biology is calm.

What should make you more cautious is the depth of the chip. Enamel is white and hard. Dentin underneath tends to look more yellow or cream-colored and feels sensitive because it contains tiny tubules that communicate with the nerve. Once dentin is exposed, cold air, water, and sweets can trigger discomfort. That is not always a same-hour emergency, but it is a same-day or next-day call.

If the center of the fracture looks pink or red, that can indicate pulp exposure. At that point, bacteria have direct access to the nerve tissue. The odds of needing more than a simple filling rise significantly. Children and teenagers, whose teeth sometimes have larger pulp chambers, can reach this point with what appears to be a modest fracture.

Another often-missed issue is the lip or tongue injury caused by the chipped edge. A jagged tooth can act like a tiny razor. Repeated trauma to soft tissue is not trivial, especially if it interferes with eating or speaking. Even when the tooth itself is not painful, smoothing that edge can make a big difference fast.

Cracks are often more urgent than chips

Cracked teeth are notoriously tricky because symptoms can be inconsistent. A patient may say, "It only hurts once in a while," or "It only hurts when I chew almonds," which can make the problem sound minor. Yet the pattern is often textbook.

When a crack opens slightly under pressure, fluid movement inside the tooth can irritate the pulp. When pressure is released, the crack snaps back and produces that electric, sharp sensation many patients describe. Sometimes there is no visible line at all. The crack may run under a filling or down the side of a cusp.

Back teeth, especially lower molars, are frequent culprits because they absorb heavy chewing forces. Teeth with large old fillings are at higher risk because less natural tooth structure remains to distribute stress. People who clench or grind commonly develop cracks gradually, then notice the problem suddenly after chewing something ordinary, like toast or granola.

A cracked tooth becomes urgent when biting is painful, the pain is spontaneous, or the tooth cannot be used comfortably. Delay can allow the crack to deepen. In some cases, a tooth that might have been saved with a crown progresses to a split tooth that requires extraction. That progression does not happen every time, but when it happens, it can happen fast.

A broken tooth after trauma is its own category

A fall, sports injury, or blow to the face deserves a different level of respect than a tooth that crumbled around an old filling. Trauma can injure not only the tooth but also the supporting bone, periodontal ligament, gum tissue, and nearby teeth that appear normal at first glance.

Front teeth are common casualties. A child hits the pool deck. An adult catches a shoulder while coaching soccer. Someone slips on a wet kitchen floor and lands awkwardly. The crown fractures, the lip swells, and adrenaline masks the extent of the injury for an hour or two. That delay is why post-trauma evaluation matters even when the tooth "doesn’t seem too bad."

One practical example from everyday dental care: a patient may present with only a corner missing from an upper incisor. The X-ray, however, shows a root fracture or damage near the apex. Another person may think the main concern is the appearance of the chipped tooth, when the more urgent issue is that the adjacent tooth has been luxated, meaning displaced in its socket.

Knocked-out adult teeth are among the clearest dental emergencies. Time outside the mouth affects Dental Emergency the survival of the ligament cells on the root surface. If an adult tooth is avulsed, immediate action improves the chance of saving it.

What to do in the first hour

The first hour after a tooth breaks can influence how straightforward treatment will be. The goal is not home repair. It is damage control.

1. Rinse gently with water to clear blood and debris.
2. If there is swelling, use a cold compress on the outside of the face in short intervals.
3. Save any broken piece, if you can find it, and keep it clean. In some cases it can help the dentist assess the fracture, and occasionally it can even be bonded back.
4. If the tooth is knocked out and it is an adult tooth, handle it only by the crown, not the root. If visibly clean, gently place it back in the socket or keep it in milk while you seek immediate care.
5. Use over-the-counter pain medication as directed, and avoid chewing on that side.

A few cautions matter here. Do not scrub a knocked-out tooth. Do not wrap it in dry tissue. Do not place aspirin directly on the gum, which can burn tissue. If the broken area is sharp, temporary dental wax from a pharmacy can protect your mouth until you are seen.

Signs you should seek same-day care, even if the break looks small

Some of the most urgent cases do not look dramatic in the mirror. Temperature sensitivity that lingers, pain when biting, a sudden bad taste, swelling near the root, or the sense that your teeth no longer fit together correctly can all indicate deeper damage.

Bite changes are especially important. If the injured tooth now contacts early, or if your jaw has to shift to close comfortably, that is not just an annoyance. It can mean a piece has moved, the tooth has fractured in a way that affects function, or swelling in the ligament is changing how the tooth seats in the bone.

Night pain is another useful clue. Teeth that ache enough to wake someone from sleep or pain that starts without chewing often signal pulpal inflammation beyond a superficial chip. Patients frequently say, "It was fine during the day, then it started throbbing tonight." That pattern should prompt a call.

Children need extra consideration. A broken baby tooth is not always an emergency in the same way a broken permanent tooth is, but trauma in the primary dentition can affect the developing adult tooth underneath. Conversely, a newly erupted permanent front tooth in a child has long-term implications if injured. Knowing whether the tooth is baby or adult changes treatment, which is one reason parents should avoid guessing.

Why waiting can make treatment more complicated

People often wait because the pain goes quiet after the first day. That can be misleading. A crack may temporarily settle, or the nerve may be transitioning from irritated to compromised. The absence of pain does not prove the tooth is safe.

There is also the mechanical problem. A damaged tooth is weaker after it fractures. Normal chewing can extend the crack, shear off another cusp, or open margins around existing fillings. The repair that might have been a bonded filling on Monday can become a crown by Friday, and in some cases a root canal the week after that.

Infection is another reason delay matters. Once bacteria move through a fracture into the pulp, the body cannot reseal that space on its own. An abscess may take days or weeks to develop. By the time swelling appears, the pathology has usually been building for a while.

Cost follows complexity. Patients understandably think waiting might save money if the issue settles. Sometimes they get lucky. More often, postponement narrows treatment options rather than widening them.

How dentists decide what treatment you need

The repair depends on how much tooth is left, whether the pulp is involved, whether the root is cracked, and whether the tooth can still be predictably restored.

A small enamel chip might only need contouring or cosmetic bonding. A larger fracture involving dentin may require a filling or onlay. If a cusp has broken from a heavily restored molar, a crown is often the most durable answer because it redistributes chewing forces and protects what remains.

If the pulp is inflamed beyond recovery or exposed, root canal treatment may be necessary before restoring the tooth. If the fracture extends below the gumline or splits the root, saving the tooth becomes far less predictable. In those cases, extraction may be the most realistic option, followed later by an implant, bridge, or removable replacement depending on the situation.

This is where experience and judgment matter. Not every cracked tooth needs a crown immediately, and not every painful broken tooth is destined for a root canal. Clinical testing, radiographs, and the pattern of symptoms

help sort out which injuries are stable and which are progressing.

The role of old fillings, grinding, and decay

Some tooth fractures are bad luck. Many are not random at all.

Large fillings weaken the remaining tooth walls over time. Every cycle of chewing places stress on those walls. Metal fillings, in particular, have historically been associated with cusp fractures in some teeth because of the way they can wedge the tooth internally, though any large restoration can leave a tooth vulnerable if enough structure is missing.

Grinding is another major contributor. Patients who clench often do not realize the force they generate at night. It is not unusual to see flattened chewing surfaces, small craze lines, and repeated fractures in the same mouth. A night guard does not repair existing damage, but it can reduce the risk of repeat injury after treatment.

Decay acts differently but just as effectively. It undermines the tooth silently. Patients sometimes report that a tooth "just broke while eating soft bread." Usually the bread is not the problem. The tooth had been hollowing out for months, and the final bite simply revealed the weakness.

What about pain control until you can be seen?

Short-term comfort measures can help, but they should not replace evaluation. Over-the-counter anti-inflammatory medication or acetaminophen, taken as directed and if medically appropriate for you, is usually more useful than home remedies. Avoid very hot, very cold, and very sweet foods. Chew on the opposite side. Keep the area clean with gentle brushing and rinsing.

Temporary dental cement from a pharmacy can be helpful if a filling or crown has come off and you need to cover exposed tooth briefly, but it is not a substitute for treatment. If a piece of tooth broke and the area is open or painful, packing it yourself tends to create more problems than it solves.

Antibiotics are not routine for every cracked or broken tooth. They may be indicated when there is swelling, spreading infection, or certain trauma patterns, but they do not fix the structural defect. This is a common misunderstanding. A fractured tooth needs a dental solution, not just a prescription.

The cosmetic side matters, but function matters more

A broken front tooth can feel devastating, even when it is not medically urgent. People notice their smile immediately. They may cover their mouth when talking or cancel plans that same day. That emotional side is real and should not be dismissed.

At the same *Dental Emergency* time, back teeth often create the more urgent biologic problems. A molar with a deep crack may not show in photos, but it carries the greater risk of pain, infection, and loss of the tooth. Dentists often have to balance these priorities, addressing urgent posterior pain while planning aesthetic repair for an anterior chip.

The good news is that modern dentistry can often do both effectively. Composite bonding can restore shape beautifully in many front tooth cases. Crowns, onlays, and other restorations can reinforce heavily damaged chewing teeth. The key is not to let appearance alone determine urgency.

So, is it a dental emergency?

Sometimes yes, emphatically yes. Sometimes no, but it still deserves prompt care. A chipped, cracked, or broken tooth crosses into emergency territory when pain is severe, the nerve may be exposed, the tooth is loose or displaced, swelling suggests infection, or bleeding and soft tissue injury do not settle. Trauma that knocks out or shifts a tooth should always be treated urgently.

If the damage is minor, painless, and stable, you may not need immediate emergency treatment, but you should still schedule an exam soon. Teeth rarely repair themselves. Small defects tend to collect stress, bacteria, and trouble.

When in doubt, call. A brief conversation with a dental office can usually sort true emergencies from next-available problems within minutes. That is better than guessing, especially with cracks, where the eye often misses what the tooth is trying to tell you.

Vitality Dental
Address: 1220 Coit Rd #106, Plano, TX 75075
Phone number: +19726454100

FAQ About Dental Emergency

What can the ER do for a tooth?

An emergency room (ER) can manage pain and treat severe infections with medication, but it cannot fix or pull a tooth.

What is considered a dental emergency?

A dental emergency is any oral health problem that involves severe pain, uncontrollable bleeding, or an infection that threatens your health or requires immediate care to save a tooth.

Is there a 24-hour dental service in Plano, TX?

There is no physical dental clinic in Plano, Texas, that stays open with walk-in staff 24 hours a day, but several offices offer 24/7 phone support, late-night hours, or same-day emergency care.